

A Professional Courtesy of:

James E. Metz, D.D.S.

General Dentist

1271 E. Broad Street
Columbus, Ohio 43205
(614) 252-4444 • Fax: (614) 252-6474
www.ColumbusDentistry.com

Memberships:

American Dental Association • Ohio Dental Association • Columbus Dental Society
American Academy of Restorative Dentistry • Pierre Fauchard Academy • International Academy of Gnathology
American College of Dentists • American Academy of Dental Sleep Medicine

PROSTHODONTICS™

NEWSLETTER

AUTUMN 2007

IN THIS ISSUE:

Clinical Trial of Occlusal Forms
For Complete Dentures

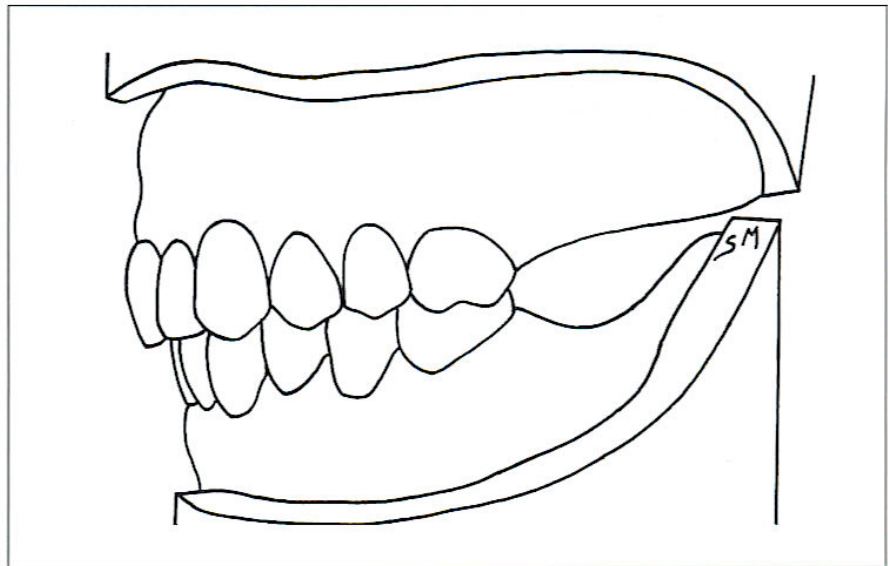
Survival of Complete Crowns
And Periodontal Health

Clinical Outcome of
IPS Empress 2 Crowns

Pulpal Response to
Cemented Porcelain Inlays

Do you or your staff have any
questions or comments about
Prosthodontics Newsletter?
Please write or call our office.
We would be happy to hear
from you.

© 2007



A randomized, controlled clinical trial investigated patients' satisfaction with 3 different occlusal schemes for conventional complete dentures. See *Clinical Trial of Occlusal Forms for Complete Dentures* inside.

Clinical Outcome of Prosthodontic Treatment

The ability to accurately predict the outcome of prosthodontic treatment is critical to effective treatment planning. Clinical studies provide the most reliable data on treatment outcomes. This issue of *Prosthodontics Newsletter* reviews a series of clinical studies on various types of prosthodontic treatment. The results of these studies can assist the dentist in planning treatment that will offer a favorable prognosis.

Clinical Trial of Occlusal Forms for Complete Dentures

There are 3 fundamental philosophical approaches to developing an occlusal scheme for complete dentures: (1) classical anatomic teeth set to cross-arch, cross-tooth eccentric balance (Figure 1); (2) lingualized occlusion (Figure 2); and (3) 0° occlusion (Figure 3). A randomized, crossover, controlled clinical trial by Sutton and McCord from the University Dental Hospital of Manchester, United Kingdom, and Glasgow Dental Hospital and School, United Kingdom, respectively, evaluated the clinical outcome of dentures made with these 3 occlusal schemes.

Forty-five patients were originally chosen for this study. Each patient received 3 conventional complete dentures in random order, each with a different occlusal scheme. The trial period for each denture was 8 weeks. The patients did not have access to the other 2 sets of dentures during the trial period to avoid direct comparison by the patients. No explanation concerning the occlusal forms or order of allocation of the dentures was provided to the patients.

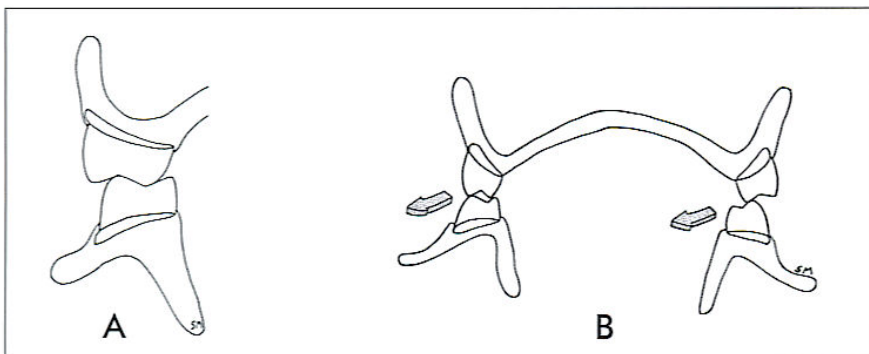


Figure 1. (A) Classical anatomic teeth in maximal intercuspation position (MIP). (B) Cross-arch, cross-tooth eccentric balance.

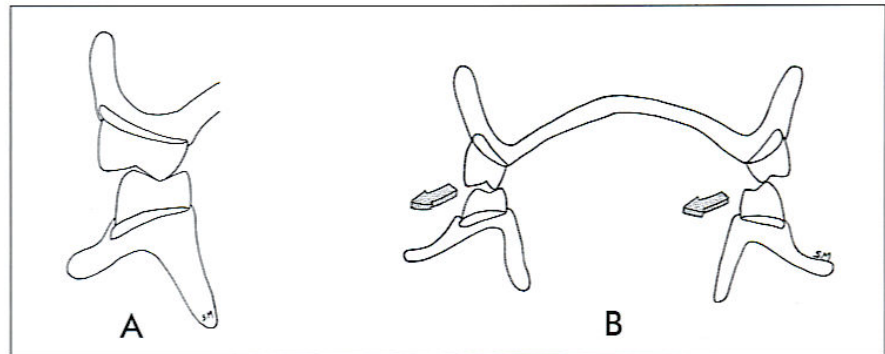


Figure 2. (A) Lingualized occlusion in MIP. (B) Cross-arch balance in eccentric positions.

Teeth with 33° cuspal inclinations (Basic 8, B range; Heraeus Kulzer) were used for the dentures with balanced anatomic occlusion. These same teeth were modified for the dentures with balanced lingualized occlusion. The teeth for the 0° occlusion (Basic 8, G range; Heraeus Kulzer) were set to a flat plane, and the dentures lacked eccentric balancing-side contacts. All dentures were remounted in a semiadjustable articulator (Denar Mark II; Waterpik Technologies Inc.) at delivery, and the occlusion was adjusted to ensure precise occlusal relationships.

The subjective evaluation of each patient of the treatment outcome for each of the 3 dentures was determined with the Oral Health Impact Profile-20 EDENT, a quality-of-life index related to oral health. The

Wilcoxon test was then used to determine statistical significance.

The dentures with lingualized occlusion were rated better than 0° teeth with regard to painful aching in the mouth, sore spots, eating ability and meal interruptions. Patients with anatomic occlusion also had significantly fewer problems eating than patients with 0° occlusion. No significant difference was found between the results recorded for lingualized occlusion and anatomic occlusion.

Comment

Pointed cusps are associated with lingualized occlusion and anatomic occlusion, and it is likely that less force was required to penetrate a bolus of food compared with the flat, 0° occlusal scheme. Greater pressure exerted with 0° teeth could explain the more frequent report of soreness associated with 0° teeth.

In general, this study provides useful clinical information. Because of the large number of patients and for practical reasons, the trial period for each denture was only 8 weeks. A longer adaptation period would have allowed the patients more time to learn to manipulate the dentures, perhaps reducing the differences noted among the 3 types of dentures. Additional similar trials that investigate other clinical vari-

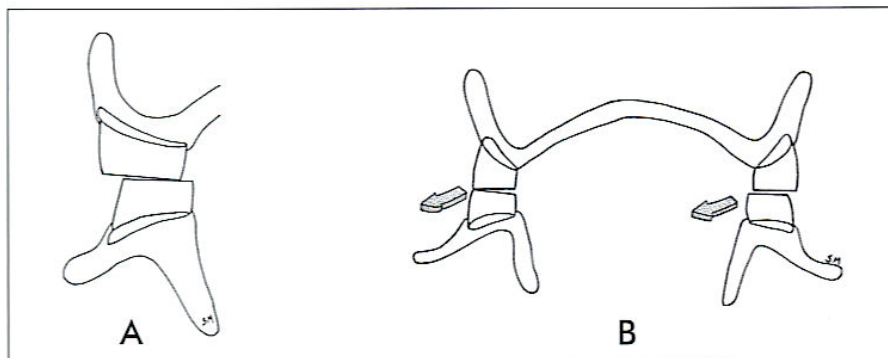


Figure 3. (A) Zero-degree occlusion in MIP. (B) Note lack of cross-arch balance in lateral occlusal position.

ables with complete denture treatment would be welcomed by the profession.

Sutton AF, McCord JF. A randomized clinical trial comparing anatomic, lingualized, and zero-degree posterior occlusal forms for complete dentures. J Prosthet Dent 2007;97:292-298.

Survival of Complete Crowns And Periodontal Health

A study by De Backer et al from Ghent University, Belgium, retrospectively evaluated 1037 complete crowns made in the undergraduate clinic of a dental school over an 18-year period. These crowns were placed in the mouths of 456 patients and represented 79% of all crowns placed at the dental school during this time period. Restorations included in the study were complete cast metal crowns, metal-ceramic crowns and 1-piece post-core crowns. The periodontal status of the study population represented a mixture of periodontally affected and non-periodontally affected patients.

Periodontal problems were addressed and oral hygiene instructions were provided before prostho-

dontic treatment was started for all patients with active periodontal disease. After prosthodontic treatment, all patients were offered a 6-month recall maintenance program. Periodontal measurements for the patients included plaque index, bleeding on probing, probing pocket depth and attachment level. The results of these measurements were used to calculate a Community Periodontal Index for Treatment Needs (CPITN) score, a measure of the severity of periodontal disease in each sextant of the mouth.

The overall survival rate for the crowns over the 18-year period was 78%. The most common cause for failure was dental caries, followed by periodontal complications. Patients with the highest CPITN score (most severe periodontal disease) at baseline were 3.8 times more likely to experience failure of a crown when compared with patients who had lower scores.

Comment

Patients with the highest CPITN scores experienced failures of the crowns for a variety of biologic and technical problems, not just because of recurrent periodontal disease. Results of this study highlight the importance of obtaining optimal periodontal health before fixed

prosthodontic treatment, as well as the need for strict recall maintenance visits.

De Backer H, Van Maele G, De Moor N, Van den Berghe L. Survival of complete crowns and periodontal health: 18-year retrospective study. Int J Prosthodont 2007;20:151-158.

Clinical Outcome of IPS Empress 2 Crowns

The IPS Empress 2 ceramic crown (Ivoclar Vivadent) is a heat-pressed lithium-disilicate glass-ceramic coping veneered with a fluoroapatite ceramic material. This crown provides excellent esthetics and natural translucency combined with high strength. Toksavul and Toman from Ege University, Turkey, conducted a clinical evaluation of 79 IPS Empress 2 crowns placed in the mouths of 21 patients.

All crowns were etched with 5% hydrofluoric acid (IPS Ceramic etching gel; Ivoclar Vivadent) and silanated (Monobond S; Ivoclar Vivadent). The teeth were etched with 37% phosphoric acid gel (Email Preparator GS; Ivoclar Vivadent) for 30 seconds. Syntac Primer (Ivoclar Vivadent) and Syntac Adhesive (Ivoclar Vivadent) were applied to the air-dried etched dentin surfaces. The crowns were then bonded with a bonding agent (Heliobond; Ivoclar Vivadent) and a dual-polymerizing composite resin cement (Variolink 2; Ivoclar Vivadent), which was light-polymerized. The U.S. Public Dental Health criteria were used to score the quality of the crowns at baseline and at 6-month intervals.

The follow-up time ranged from 12–60 months. The survival rate, as determined by Kaplan-Meier statis-

tics, was 95.24%. Only 1 crown fractured: an endodontically treated tooth without a post-and-core fractured beneath its crown at the cervical margin.

Comment

The majority of the crowns in this study were placed in the maxillae on incisors, canines and premolars where esthetic concerns are more critical. The overall results are very encouraging. Caries was not detected for any of the crowns, and only 1 tooth exhibited postoperative sensitivity, suggesting that the somewhat complicated cementation system was effective at sealing the margins of the crowns against microleakage.

Toksavul S, Toman M. A short-term clinical evaluation of IPS Empress 2 crowns. Int J Prosthodont 2007;20:168-172.

Pulpal Response to Cemented Porcelain Inlays

A study by Vigolo et al from the University of Padova, Italy, evaluated the pulpal response to porcelain inlays cemented with an adhesive resin cement 1 year after cementation. Eight patients requiring extraction of the maxillary and mandibular first premolars for orthodontic reasons were chosen for the study.

All teeth were unblemished. Porcelain MOD inlays were placed in 3 randomly selected first premolars for each patient; the remaining

unrestored premolar served as a control. The teeth were prepared with a high-speed handpiece for the inlays with diamond stones and copious water irrigation. The tooth preparations ended entirely in enamel.

One week after tooth preparations and impressions, the inlays were bonded. The inlays were airborne-particle-abraded with 50-µm aluminum oxide, etched with hydrofluoric acid (Cerec etching gel; Vita Zahnfabrik) for 1 minute, and then silanated (Monobond-S; Ivoclar Vivadent). Cementation was performed under rubber dam.

The enamel was etched with 37% phosphoric acid (Total-Etch; Ivoclar Vivadent). The dentinal surfaces were conditioned with 4% malic acid (Syntac Primer; Ivoclar Vivadent) for 15 seconds. The adhesive (Syntac Adhesive; Ivoclar Vivadent) and resin cement (Heliobond; Ivoclar Vivadent) were applied, and the inlays were seated. Excess cement was wiped away, and the cement was light polymerized. The occlusion was adjusted and then polished.

One year later, all 32 teeth (24 with porcelain inlays and 8 controls) were extracted. The roots of the teeth were sectioned with a diamond wheel, followed by immediate fixation of the pulpal tissues. The teeth were dehydrated, decalcified, embedded in resin (SamplKwick; Buehler), sectioned, and stained with Eosine-Ematossiline solution for microscopic examination. Randomly chosen sections were viewed under a microscope up to 600×.

Neither the control teeth nor the experimental teeth displayed inflamed pulpal tissue. The pulps were free of polymorphonuclear leukocytes, mononuclear lymphocytes and bacteria. An analysis of variance (ANOVA) of the data indicated no difference between the 2 groups.

Comment

Five of the 8 patients in this study experienced some degree of sensitivity after cementation of the porcelain inlays that resolved in 10-15 days. The sensitivity did not recur, and none of the inlays demonstrated any problems during the 1-year study period. Sensitivity can be the result of trauma to the pulp that would occur during tooth preparations or from the acidic solutions used during the cementation phase. If the margins of the restorations had not been adequately sealed, microleakage of bacteria could have occurred at the interface, which could produce chronic sensitivity and dental caries. It appears that the meticulous steps involved in the cementation process sealed the margins of the inlays adequately, preventing bacterial ingress and sensitivity.

Vigolo P, Graiff L, Mutinelli S, Fonzi F. Porcelain inlays cemented with composite resin cement: an in vivo investigation of pulpal reaction one year following cementation. J Prosthodont 2007;16:123-128.

NEXT:

- Immediately loaded mandibular overdentures
- Accuracy of impressions made with angulated implants
- Maxillary implant-supported overdentures

Our next report features a discussion of these issues and the studies that analyze them, as well as other articles exploring topics of vital interest to you as a practitioner.

